



Case Report : Laparoscopic Spleen Preserving Distal Pancreatectomy for Insulinoma

*Prof. Dr. Gajanan R. Ekbote, Asso. Prof. Dr. Shailesh Puntambekar
Dr. Arvind Giram, Dr. Ahsan Zuberi

**Prof. of Surgery, B. J. Medical College, Pune 411001.*

Abstract

We report a case of a 67-year-old male patient with an insulinoma of pancreas at the junction of body and tail. He underwent a laparoscopic spleen preserving distal pancreatectomy. Patient presented with episodes of giddiness and drowsiness for past 4 months. There was also history of tremor on exertion since 4 months. His symptoms improved with intake of food. During his episodes his blood sugar levels ranging from 35 mg% - to 50 mg%. Patient was thoroughly evaluated. USG abdomen and MRI abdomen showed normal study. His fasting serum insulin level raised with normal ACTH and cortisol level. DOTA PET Scan suggestive of focal octreotide receptor expressing lesion at the junction of body and tail of pancreas. There were no postoperative complications, and the patient was discharged from the hospital on day 6. The patient was ambulatory soon after the procedure. He was allowed to take oral liquids after 12 hrs post surgery, and his hospital stay was short; therefore, the surgery was judged to have been highly useful.

Introduction

Insulinoma is the most common neuroendocrine tumor of the pancreas. Peak incidence of occurrence is between 40 to 69 years. About 40% - 90 % of tumors are nonfunctional. Rest of them manifest with evident hormonal symptoms. Of the functional tumors 70% are insulinoma, of which 90% are benign. Usually present with symptoms like anxiety, confusion, dizziness, headaches, and sweating. Treatment for **insulinoma** is surgical excision, however before surgery; symptoms of excess hormones must be corrected. Patients with neuroendocrine tumor after surgery generally do well for years. Distal pancreatectomy (DP) is the removal of the pancreatic tissue at the left side of the

superior mesenteric vein and it is traditionally approached by an open or laparoscopic exposure. Preservation of the spleen is optional but appears to have a better immunological outcome.

In 1994, Soper et al first performed laparoscopic distal pancreatectomy in a pig model to document its safety and feasibility¹. Laparoscopic partial pancreatic resection for pancreatic endocrine tumor was first reported in 1996 by Gagner and colleagues², and laparoscopic pancreatectomy is now considered to be indicated for that condition³.

Case Summary

67 year male patient presented with history of episodes of giddiness, drowsiness for past 4 months. There also history of tremor on exertion since 4 months. His symptoms improved with intake of food. During his episodes his blood sugar levels ranging from 35 mg% - to 50 mg%.

Investigations

Patient was thoroughly evaluated. USG abdomen and MRI abdomen showed normal study. His fasting serum insulin levels were raised with normal ACTH and cortisol level. DOTA PET Scan suggestive of focal octreotide receptor expressing lesion at the junction of body and tail of pancreas. Complete hemogram was done. ECG, X-ray chest.

ACTH, Sr.Cortisol, Sr.Insuline, Thyroid function test and random blood sugar done preoperatively.

Operative Procedure

After taking written informed consent patient was taken for "LAPAROSCOPIC SPLEEN PRESERVING DISTAL PANCREATECTOMY". After port placement lesser sac was opened and pancreas was identified. Meticulous dissection was done at the lower border of pancreas. Splenic vein and splenic artery were identified. Small branches from both vessels were clipped and cut. After



complete mobilization of distal pancreas. ENDO GIA stapler blue cartridge was used for transaction of the pancreas at mid body region. Specimen was packed in endobag and removed. Total operative time taken was 120 min. Estimated blood loss was 50 ml. Gross examination of specimen suggested 2.2x1 cm, hard nodule in tail of pancreas. Patient tolerated the procedure well and was shifted to ward.

Post Operative Period

Patient's blood sugar levels normalized post operatively. Ryle's tube was removed on post operative day 2 and oral liquids were started. Patient was discharged on day 6.

Final histopathology examination report was "Low grade neuroendocrine tumor of pancreas, surgical margin are free." Size of tumor 1.5x1x1 cm.

Ki 67 index was 1.5.

Histopathology Report of Surgical Specimen ⁴

Nature of specimen: Distal pancreatectomy

Gross Examination :

Distal part of pancreas 5.5x3.5x2.5 cm with small circumscribed nodule 1.5x1x1 cm (separated).

Rest of the pancreas is unremarkable

ABC – Pancreas random D - Nodule

E- Pancreatic margin.

Microscopy : Distal Pancreatectomy

- Pancreatic tumor (1.5x1x1) - Low Grade Neuroendocrine tumor.

Cells are arranged in rosettes acinar & gyriform pattern. Tumor cells are small round having monomorphic round nuclei with stippled chromatin & granular eosinophilic cytoplasm. Mitotic activity is < 2/10 hpf
No necrosis. No stromal invasion

- Lymphovascular emboli & capsular invasion noted. No perineural invasion.
- Rest of the pancreatic parenchyma shows no significant pathology.
- Surgical margins free of tumor

Impression :

Low Grade Neuroendocrine tumor – Pancreas.

Surgical margins free

Suggestion : Ki-67 labelling index.

Immunohistochemistry Report

Specimen : Pancreatic tumor biopsy.

Clinical : Pancreatic tumor.

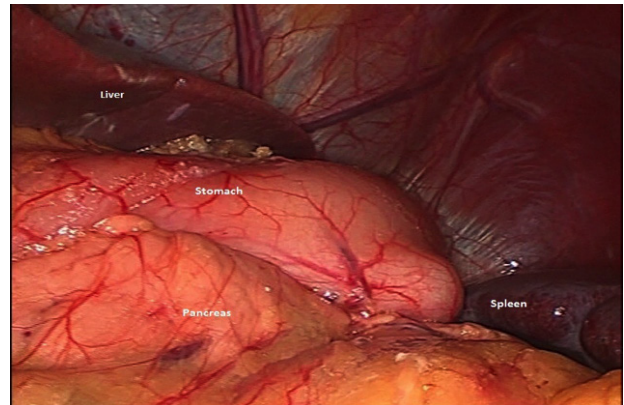
Test : Ki- 67

Immunohistochemistry result

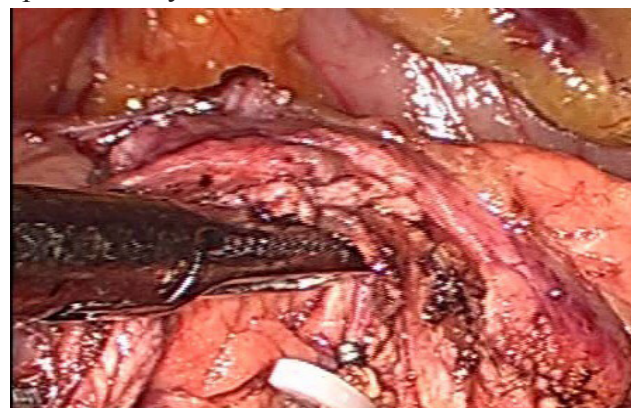(Mib – 1 labelling) Ki-67 ---- 1.5%

Intra Operative Images

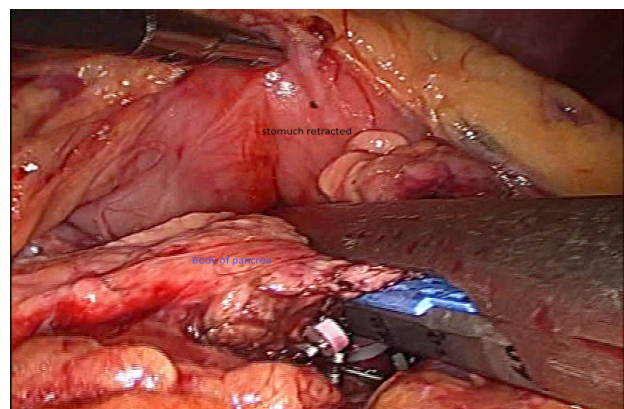
Laparoscopic view of pancreas, spleen, liver and stomach



Laparoscopic view after dissection showing splenic artery and vein

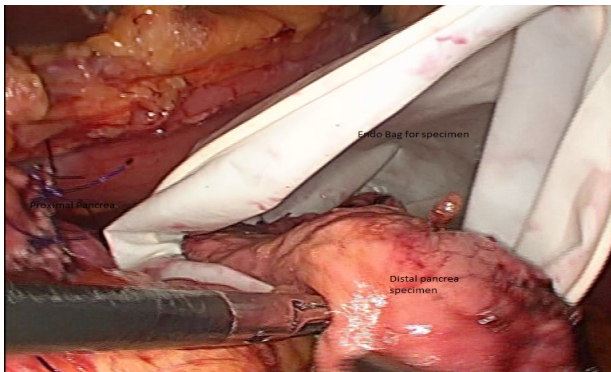


Illustrating view of laparoscopic distal pancreatectomy with ENDO GIA stapler

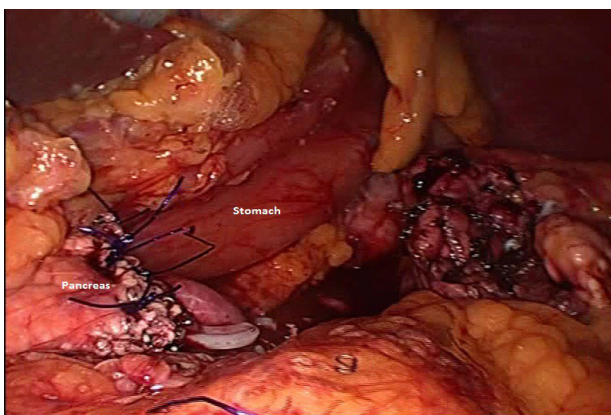




Specimen extracted in endo bag



Post distal pancreatectomy view of pancreas



Discussion

Neuroendocrine tumor arises from cells throughout diffuse endocrine system, mostly arising from lung, bronchi, bowel, pancreas and less commonly from parathyroid, thyroid and adrenal.⁵ Most of these are sporadic in nature but sometimes can in context of inherited genetic syndrome like MEN 1 and MEN 2.⁶ Neuroendocrine tumors are sub classified by the site of origin, stage, functional status and histological differentiation (mitotic count, Ki-67 index and tumor grade).⁵

Suspicion of neuroendocrine tumor of pancreas usually occurs when patient presents with symptoms of hormonal excess if it is a functional secretory tumor or is an incidental finding in a non-functional tumor.⁵ Biochemical test include Serum Chromogranin –A which is positive in 60% of cases. Serum insulin level ($>6\text{mIU/ml}$),

pro-insulin ($\geq 5\text{ pmol}$) and c-peptide (0.6ng/ml) and fasting blood sugar less than 55mg/dl is diagnostic for insulinoma. Radiologically EUS is the best modality to particularly localize the tumor.^{5, 6} MDCT or MRI is best to rule out metastasis.^{5, 6} Somatostatin scintigraphy is less useful in insulinoma as these tumors are less sensitive for octreotide derivatives, and used only for metastatic disease follow up if octreotide derivatives are being used.⁶

Resection is the primary treatment of choice which is usually enucleation for lesions $<1\text{ cm}$ away from MPD, for lesions $1\text{-}2\text{ cm}$ either enucleation or radical surgery (Pancreaticoduodenectomy / Distal pancreatectomy +/- splenectomy) with regional lymphadenectomy is advocated and for lesions $>2\text{ cm}$ radical surgery with lymphadenectomy.⁷ Laparoscopic surgical management is the current trend especially Distal Pancreatectomy with or without splenectomy as it is a less morbid, gives early postoperative patient recovery, but at the same times requires high level of surgical expertise.⁶

Surveillance is advocated every 3 monthly with MDCT or MRI along with serum markers for at least 10 years. Treatment for metastatic disease if operable then surgery followed by Somatostatin analogue therapy with or without chemotherapy.⁶

Conclusion

We have reported a case of laparoscopic distal pancreatectomy, with preservation of the spleen and splenic vessels is easy and safe. There was no major intraoperative bleeding. The patient was ambulatory soon after the procedure. He was allowed to take orally after 12 hrs post surgery, and his hospital stay was short; therefore, the surgery was judged to have been highly useful.



References

1. Soper NJ, Brunt LM, Dunnegan DL, Meininger TA. Laparoscopic distal pancreatectomy in the porcine model. *Surg Endosc* 1994; 8: 57-60; discussion 60-1 [PMID: 8153866 DOI: 10.1007/BF02909495]
2. Gagner M, Pomp A, Herrera MF: Early experience with laparoscopic resections of islet cell tumors. *Surgery* 1996; 120: 1051—1054.
3. Gumbs AA, Gres P, Madureira F, Gayet B: Laparoscopic vs. open resection of pancreatic endocrine neoplasms: single institution's experience over 14 years. *Langenbecks Arch Surg* 2008; 393: 391—395.
4. Kadam Diagnostic lab, Aundh, Pune lab report.
5. Baily & Love's Short Practice of Surgery (26th Ed.) 52:788-795, 63:1055.
6. Sabiston textbook of Surgery (19th Ed.) 42:995-1008, 40: 951-960.
7. Schwartz's Principle of Surgery (10th Ed.) 33:1391-1392.